

# Congenital Preputial Ostium Atresia and Persistent Penile Frenulum in a 3-Month-Old German shepherd Dog

Linda C. Omosekeji,<sup>1\*</sup> Moyinoluwa J. Onoja,<sup>2</sup> Cecilia O. Oguntoye,<sup>3</sup> Oluwatoyin O. Ajala,<sup>4</sup> Olufisayo O. Leigh,<sup>5</sup> and Oghenemega D. Eyarefe<sup>6</sup>

<sup>1,2,4,5</sup> Department of Theriogenology, Faculty of Veterinary Medicine, University of Ibadan

<sup>3,6</sup> Department of Veterinary Surgery and Radiology, Faculty of Veterinary Medicine, University of Ibadan

\*Corresponding author: Linda C. Omosekeji; [lindaagbugba@gmail.com](mailto:lindaagbugba@gmail.com)

<https://doi.org/10.21608/svu.2024.330756.1350>

**Copyright:** © Linda C. Omosekeji et al. This is an open access article distributed under the terms of the creative common attribution license, which permits unrestricted use, distribution and reproduction in any medium provided the original author and source are created.

Receive Date: 23 October 2024 Accept Date: 12 December, 2024 Publish Date: 3 January, 2024



## ABSTRACT

Congenital abnormalities affecting the reproductive system of male animals have been reported over the years. Due to hereditary predisposition, affected animals are culled from breeding programs. A 3-month-old male German Shepherd dog was presented to the Theriogenology Unit of the Veterinary Teaching Hospital, University of Ibadan, Nigeria, with a complaint of a distended preputial pouch. On examination, only a pinpoint fistulous opening where urine was seen to void was observed and the penis was palpable within the preputial pouch. Before surgical intervention, blood was collected for haematology and serum chemistry while aspirate from the swelling was taken for cytological evaluation and microbial culture. Cytological evaluation of the aspirate revealed an abundance of neutrophils while the microbial culture yielded no growth. Surgical intervention to construct the preputial orifice by making a triangular incision at the dorsal aspect of the prepuce around the pinpoint opening to remove a flap of tissue and create an orifice was successful. During the surgical construction of the preputial orifice, a persistent penile frenulum severed from its ventral attachment to the preputial mucosa was discovered. The puppy recovered fully following the correction of both anomalies and suture removal at 14 days post-surgery. The presence of concurrent congenital reproductive anomalies in an animal indicates embryological developmental disorder, which negatively impacts reproduction. This case heightens the importance of consulting veterinary clinicians for a thorough physical examination before purchasing any animal, especially when such is intended for breeding.

**Keywords:** Reproduction, congenital, dog, penile, male

## INTRODUCTION

Several male reproductive tract abnormalities have been reported in various species of animals. These abnormalities may be congenital or acquired and associated with

either asymptomatic or symptomatic evidence of breeding failure, urinary system dysfunction, or both (Olsen and Salwei, 2001). Most penile and preputial defects are heritable; hence correction is aimed at improving associated

urinary tract dysfunction rather than for breeding (Papazoglou and Kazakos, 2002). Reported congenital anomalies of the prepuce and penis in dogs include incomplete development of the prepuce (Mialot et al., 1984), interruption of the caudal part of the prepuce (Domínguez et al., 1996), stenosis of the preputial orifice (Sarieler and Kara, 1998), persistent penile frenulum (Olsen and Salwei, 2001) and phimosis (Papazoglou and Kazakos, 2002). Congenital preputial atresia or stenosis has been reported to be common in breeds such as Labrador retrievers, German shepherds, Bouvier des Flandres, and golden retrievers (Papazoglou and Kazakos, 2002; Arthur et al., 1996).

Surgical correction of these congenital anomalies in the male requires a good understanding of the urogenital system anatomy. Sexual differentiation during embryologic development is an important aspect of reproduction. It occurs in three important steps according to this order which are sex chromosome establishment, gonadal differentiation, and phenotypic sexual development. Development of the reproductive system occurs following the formation of the urogenital ridge from the mesodermal tissue of the embryo (Griffin et al., 2019). The urogenital ridge splits into the genital ridge and nephrogenic cord (forms the urinary tract). There is migration of primordial germ cells from

the yolk sac to the genital ridge of the embryo which is important for gonad formation (Griffin et al., 2019). The gonads are formed based on the chromosomal sex, and their presence directs further formation of internal and external genitalia. Once the testes are formed, they produce certain hormones (testosterone, dihydrotestosterone, Mullerian inhibitory substance) necessary for the development of the Wolffian duct to the male ducts and external genitalia (Nef and Parada, 2000). Under the influence of testosterone, the tubular duct of the male is formed from the Wolffian duct (i.e., the epididymis and vas deferens). The Mullerian inhibitory substance causes the regression of the Mullerian duct. Dihydrotestosterone influences the formation of the prostate and urethra from the urogenital sinus, the penis from the genital tubercle, the scrotum, and prepuce from the surface ectoderm and genital swellings (Griffin et al., 2019).

The genital tubercle is the embryological source of the penis (Cohn, 2011). At the distal tip of the formed penis, a circular plate made of ectodermal cells progressively invaginates into the mesenchyme of the genital tubercle, thickens, and splits into two layers, forming the preputial cavity. The external border of the two layers of the ectodermal plate forms the preputial orifice (Hermanson, and Lahunta, 2018). The penis in a retracted state is covered by the prepuce. The prepuce consists of an

internal and an external lamina, which is continuous at the ostium preputiale (Hermanson and Lahunta, 2018). Also, a thin layer of connective tissue that connects the glans penis to the foreskin, called penile frenulum, exists. The penile frenulum may be present or absent at birth in male animals and if present, it ruptures spontaneously at puberty in response to androgenic hormone (Papazoglou and Kazakos, 2002; Boothe, 2008; Wolfe and Rodning, 2009). When the penile frenulum persists, it interferes with reproductive and urinary functions in the male necessitating surgical intervention to separate the penis from the foreskin (Garcia et al., 2019).

In this paper, we report a case of congenital atresia of the preputial ostium and persistent penile frenulum in a 3-month-old male German Shepherd dog presented to the Theriogenology Unit of the Veterinary Teaching Hospital, University of Ibadan, Nigeria.

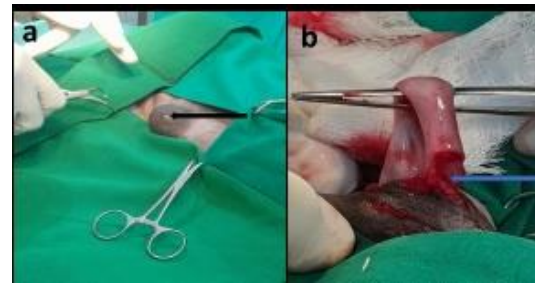
## CASE PRESENTATION

### History

A 3-month-old male German Shepherd dog was presented to the Theriogenology Unit of the Veterinary Teaching Hospital, with a complaint of swelling of the preputial sheath which was observed about 2-months earlier.

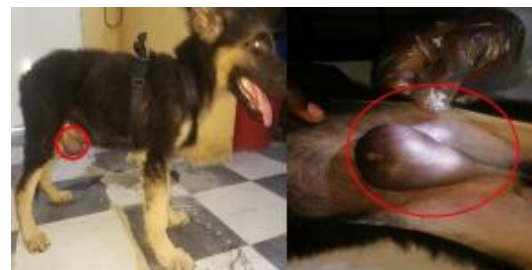### Physical Examination

Physical examination revealed a normal mucous membrane (pinkish), moist muzzle,



**Figure 2: Showing pinpoint fistulous preputial opening (A- black arrow) and persistent penile frenulum (B- blue arrow)**

absence of ectoparasite, and a congenital malformation of the preputial orifice. The preputial sheath appeared as a fluid-filled



**Figure 1: Showing the congenital malformation of the prepuce which appeared as a fluid-filled pouch with a pin-point opening both in standing and dorsal recumbency.**

pouch with a pin-point opening that allowed the passive passage of urine (Figure 1). The penis could be palpated within the distended preputial pouch which was about 3cm. No reaction to pain was observed on palpation of the penis. The testes were freely movable and palpable within the scrotum.

### Physiological parameters

The physiologic data (Temperature -38.2°C, Heart rate -120 beats per minute, Respiratory rate -18 breaths per minute, Capillary Refill

Time- <2 minutes and lymph node integrity were within normal ranges.

## Sample Collection

Blood (5 ml) was collected in heparinised and non-heparinised tubes, for haematology and serum chemistry respectively. An amber-colored, odourless fluid was aspirated from the preputial pouch and submitted for cytological evaluation, microbial culture, and antibiotic sensitivity test.

## Haematology and serum chemistry report

This report (Table 1) showed that the plasma protein, fibrinogen, haemoglobin, packed cell volume, red blood cell count, total protein, and albumin were lower when compared to the normal reference ranges. This may be attributed to the age of the puppy because significant differences have been reported to exist in baseline values for young and mature animals (Klaassen, 1999). All other haematology and serum chemistry parameters were within the normal reference ranges (Fielder, 2022a; Fielder, 2022b). Also, no hemoparasite was seen in the blood.

## Cytology report

The aspirated fluid was turbid with a pH of 6, protein of 4.6 g/dL, glucose 2+, and specific gravity of 1.028. Its smear showed a flocculent globular lipid-like background with a low cellular yield of round cells with abundant

vacuolated/fatty cytoplasm. There were numerous neutrophils indicating the presence of inflammation.

## Microbial Culture Report

The culture of the aspirate yielded no growth of microbes after 48 hours of incubation at 37°C.

## Differential Diagnosis

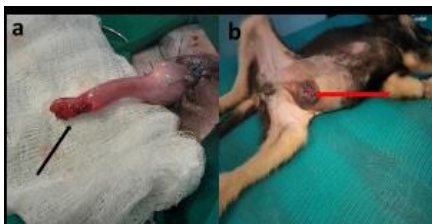The possible differentials considered during the observation of the puppy were posthitis, preputial stenosis, and penile injury.

## Surgical reconstruction of the prepuce:

The puppy was premedicated with chlorpromazine hydrochloride (Thorazine®, Hikma Farmacêutica, Portugal) at 4 mg/kg and pentazocine lactate (Talwin®, Sanofi Aventis, Canada) at 2mg/kg body weight respectively via the intramuscular route. The epidural nerve block was achieved with a mixture of lidocaine hydrochloride (Glocain®, Vital Health Care PVT Ltd, India) and bupivacaine (Marcain®, Abbott Healthcare Pvt. Ltd, India) at 0.5ml/6kg of both drugs at the lumbosacral space to achieve analgesia and muscle relaxation. The preputial region was prepared for aseptic surgery.

The puppy was placed on dorsal recumbency. A triangular skin incision was made at the point of the pin-point opening and continued to the preputial sac (Figure 2) to allow for exteriorization of the penis which also revealed a persistent penile frenulum (Figure 2).

The penis was carefully separated at the penile frenulum (Figure 3). The skin was sutured to the underlying mucosa with size 2-0 nylon suture



**Figure 3: Showing penis (A- black arrow) and preputial orifice (B- red arrow) after surgical correction of the anomalies.**



**Figure 4: Showing the dog after suture removal at 14 days post-surgery.**

material using a simple interrupted suture pattern. The surgery was completed within an hour. Amoxicillin at 25mg/ml twice daily per os for 5 days. Tramadol (Ultram® 50mg tablet, Jansen pharms, Belgium) was dispensed at a dosage of 3mg/kg body weight 12 hourly for one-week post-surgery. An Elizabethan collar was fixed to prevent licking and self-mutilation. Daily monitoring revealed normal physiological parameters. The dog was represented after 14 days following healing for suture removal

(Figure 4). The dog's recovery was uneventful. Subsequent follow-up after 3 months revealed the stud was fine and had no challenges associated with the surgery.

## DISCUSSION

Congenital anomalies affecting the reproductive system may be unnoticed especially when they are not associated with urinary tract dysfunction. Such conditions may be diagnosed during infertility investigation (Papazoglou and Kazakos, 2002). In this case, the early diagnosis was made due to the apparent preputial ostium atresia that resulted in urine retention in the formed pouch. An attempt at preputial sheath reconstruction revealed a persistent penile frenulum which was concurrently excised. Although, the penile frenulum may rupture spontaneously, excising it is important because it directs urine flow toward the animal's body which often leads to dermatitis (Papazoglou and Kazakos, 2002).

Several preputial congenital anomalies such as congenital atrophy of the caudal prepuce (Dominguez *et al.*, 1996), incomplete development of the prepuce (Mialot *et al.*, 1984), congenital shortened prepuce (Feldman and Nelson, 2004), congenital preputial atresia (Meilán, 2006), congenital preputial stenosis with tissue remnants connecting dorsal and distal aspects of the penis with the prepuce as well as persistent penile frenulum (Olsen and Salwei, 2001) and congenital preputial atresia

with unilateral cryptorchidism (Acai *et al.*, 2021) have been reported. However, the present findings are slightly similar to the report by Olsen and Salwei. (2001), the difference lies in the association of the congenital preputial stenosis with tissue remnants connecting the dorsal and distal aspects of the penis with the prepuce. The resultant effect of the congenital atresia of the preputial ostium is congenital phimosis (Papazoglou and Kazakos, 2002); a condition that has also been associated with preputial trauma (Papazoglou and Kazakos, 2002). Breed predisposition to congenital preputial anomaly has not been recorded, however, the condition has been reported in German shepherds, Labrador, Mongrel, Great Pyrenees, Bouvier de Flandres, and mixed-breed dogs (Hobson, 1993; Olsen and Salwei, 2001; Acai *et al.*, 2021). Persistent frenulum has been reported in Pekingese, cocker spaniels, miniature poodles, and mixed-breed dogs (Hobson, 1993; Papazoglou and Kazakos, 2002; Kumar and Rohilla, 2024). This condition may be asymptomatic or symptomatic with signs such as urine scalding, penile deviation during erection, preputial and penile licking, urine retention, abnormal voiding of urine, and even secondary penile infection (Hobson, 1993; Root Kustritz, 2001; Papazoglou and Kazakos, 2002). In this case, surgical management resolved the apparent preputial abnormality and persistent frenulum. Surgical management has been a

proven therapeutic approach for congenital conditions of the urogenital system (Garcia *et al.*, 2019).

Congenital anomalies in the male have been linked to defects in the metabolism of androgenic hormones which are important in phenotypic sexual differentiation during embryo development (Uda *et al.*, 2004). These conditions have been associated with disorders of sexual development and had previously been reported in some cases of intersex (Romagnoli and Schlafer, 2006), however, there is a lack of information on the genetic implication of congenital phimosis and persistent penile frenulum. It is recommended that the male dog should not be used for breeding because of the hereditary predispositions of congenital reproductive anomalies, which has been reported by Papazoglou (2004). The propagation of these conditions can be prevented by culling animals with congenital reproductive anomalies and ensuring that exposure to substances capable of causing teratogenic effects is limited as much as possible. The prognosis for these congenital anomalies is usually good if there are no surgical complications.

## CONCLUSION

Congenital urogenital conditions could pose severe health challenges especially when

they are not quickly presented for management. This case heightens the need to consult veterinary clinicians for a thorough physical examination before purchasing any animal, especially when such is intended for breeding.

## CONFLICT OF INTEREST

The authors declare they have no conflicts of interest.

## AUTHORS CONTRIBUTION STATEMENT

ALC and OMJ attended the case at a presentation in the Theriogenology unit under the consultant supervision of AOO and LOO. OCO was the anesthesiologist during the surgical treatment while EOD was the chief surgeon. ALC, OMJ, and OCO wrote the first draft of the manuscript. EOD corrected the draft manuscript. All reviewed and approved the final manuscript.

## REFERENCES

- Acai, J.O., Agwai, B., Yusuf, A. and Semazzi, P. (2021). A Rare Case of Preputial Atresia with Unilateral Cryptorchidism in a Six-Month Old Mongrel. *Int J Vet Sci Med Diagn*, [online] 2(2). doi:<https://doi.org/10.36266/IJVSMD/111>.
- Arthur, G. H., Noakes, D. E., Pearson, H. and Parkinson, T.J. (1996) *Veterinary Reproduction and Obstetrics*. 7th ed. London: Saunders, p: 714-24.
- Cohn, M.J. (2011). Development of the external genitalia: Conserved and divergent mechanisms of appendage patterning. *Developmental Dynamics*, 240(5), pp.1108–1115. doi:<https://doi.org/10.1002/dvdy.22631>.
- Dominguez, J. C., Anel, L., Pena, F. J., & Alegre, B. (1996). Surgical correction of a canine preputial deformity. *Veterinary Record*, 138(20), 496–497. doi:[10.1136/vr.138.20.496](https://doi.org/10.1136/vr.138.20.496)
- Feldman, E.C. and Nelson, R.W. (2003). *Canine and Feline Endocrinology and Reproduction*, 3rd Edition. [online] [vetbooks.ir](https://vetbooks.ir). Available at: <https://vetbooks.ir/canine-and-feline-endocrinology-and-reproduction-3rd-edition/> [Accessed 9 Jul. 2024].
- Fielder, S. E. (2022a). Serum biochemical analysis reference ranges. *MSD Manual Veterinary Manual*. <https://www.msdvetermanual.com/special-subjects/reference-guides/serum-biochemical-analysis-reference-ranges>
- Fielder, S. E. (2022b). Haematology reference ranges. *MSD Manual Veterinary Manual*. <https://www.msdvetermanual.com/special-subjects/reference-guides/hematology-reference-ranges>
- Garcia, J. C. J., Silva, M. F. and Angrimani, D. S. R. (2019). Persistence of congenital penile frenulum in male cat: case report. *Braz J Vet Res Anim Sci*. 56(2):e151959. <https://doi.org/10.11606/issn.1678-4456.bjvras.2019.151959>.
- Griffin, B., White, S., and Kustritz, M. V. R. (2019). Disorders of Sexual Development and Common Reproductive Pathologies. *High-Quality, High-Volume Spay and Neuter and Other Shelter Surgeries*, 27–51. doi:[10.1002/9781119646006.ch2](https://doi.org/10.1002/9781119646006.ch2)
- Hermanson, J.W. and Lahunta, A. de (2018). *Miller and Evans' Anatomy of the Dog - E-Book*. [online] [Google Books](https://books.google.com). Elsevier Health Sciences. Available at: <https://books.google.com/ng/books?id=state.+This+skin+fold+consists+of+an+inter+nal+and+an+external+lamina> [Accessed 9 Jul. 2024].

- Hobson, H.P. (1993). 'Surgical pathophysiology of the penis,' in *Disease Mechanisms in Small Animal Surgery*. ed. M. J. Bojrab (Philadelphia, Lea & Febiger). 552–559..
- Kumar, A. and Rohilla, S. (2024). Case report of surgical correction for persistence of congenital penile frenulum in a dog. *International Journal of Veterinary Sciences and Animal Husbandry*. 9(4):93-95.
- Klaassen, J.K. (1999). Reference Values in Veterinary Medicine. *Laboratory Medicine*, 30(3),pp.194–197.  
doi:<https://doi.org/10.1093/labmed/30.3.194>.
- Meilan, J. (2006). Rare preputial anomaly and its surgical correction in a dog. *Veterinary Record*, 158(19), pp.672–672.  
doi:<https://doi.org/10.1136/vr.158.19.672>.
- Mialot, J.P., Bégon, D. and Guérin, C. (1984). Reproductive pathology in domestic carnivores. ed. Maisons-Alfort from 'Veterinary point'. 187-189.
- Nef, S. and Parada, L.F. (2000). Hormones in male sexual development. *Genes Dev*. 14: 3075–3086.
- Olsen, D.B. and Salwei, R.M. (2001). Surgical correction of a congenital preputial and penile deformity in a dog. *Journal of The American Animal Hospital Association*, 37(2), pp.187–192.  
doi:<https://doi.org/10.5326/15473317-37-2-187>.
- Papazoglou, L.G. and Kazakos, G.M. (2002). Surgical conditions of the canine penis and prepuce. *Compendium: Small animal/exotics*. Vol. 24 (3): 204-218.
- Papazoglou, L.G. (2004). Diseases and Surgery of the Canine Penis and Prepuce. *World Small Animal Veterinary Association World Congress Proceedings, 2004*.  
<https://www.vin.com/apputil/content/defaultadv1.aspx?pld=11181&meta=generic&catId=30097&id=3852322&print=1>
- Romagnoli, S. and Schlafer, D. H. (2006). Disorders of Sexual Differentiation in Puppies and Kittens: A Diagnostic and Clinical Approach. *Veterinary Clinics of North America: Small Animal Practice*, 36(3), 573–606. doi:10.1016/j.cvsm.2005.12.007
- Root Kustritz, M.V. (2001). Disorders of the Canine Penis. *Veterinary Clinics of North America: Small Animal Practice*, 31(2), pp.247–258.  
doi:[https://doi.org/10.1016/s0195-5616\(01\)50203-x](https://doi.org/10.1016/s0195-5616(01)50203-x).
- Sarierler, M. and Kara, M.E. (1998). Congenital stenosis of the preputial orifice in a dog. *Veterinary record/The oeveterinary record*, 143(7),pp.201–201.  
doi:<https://doi.org/10.1136/vr.143.7.201>.
- Uda, A., Kojima, Y., Hayashi, Y., Mizuno, K., Asai, N. and Kohri, K. (2004). Morphological features of external genitalia in hypospadiac rat model: 3-dimensional analysis. *Journal of Urology* 171, 1362–1366
- Wolfe, D. and Rodning, S. P. (2009). Diagnosis and management of juvenile anomalies of the penis and prepuce. In: Anderson DE, Rings DM, editor. *Food animal practice*. 5th ed. Saint Louis: Saunders. p. 340-42.  
<http://dx.doi.org/10.1016/B978-141603591-6.10073-9>.